

## Future Challenges in Acute Right Heart Failure

Markus W. Ferrari\*

XXXXXXXXXXXXXXXXXXXXXXXXXXXX

### Introduction

Physiologically, with every stroke right and left ventricle ejects the same blood volume. However, due to low resistance of the pulmonary circulation the stroke work is about 75% lower than on the left side resulting in a thinner right ventricular wall. Therefore, the right ventricle shows more compliance and less resistance to an abrupt increase in after load. Acute Right Heart Failure (ARHF) is a clinically complex situation occurring in 10 to 20% of all acute heart failure patients mostly due to right coronary occlusion or secondary pulmonary hypertension [1,2]. It is characterized by an inability of the right ventricle to generate enough cardiac output, thereby resulting in a volume deficit of the left ventricle. In addition, ARHF results in an increase in venous congestion and finally in cardiogenic shock. The prognosis of ARHF is extremely dismal. Treatment of this life-threatening clinical condition primarily focuses on treating the cause of acute right ventricle failure. In addition, optimization of preload status by volume infusion, reduction of after load, improving contractility by adequate pharmacotherapy, and mechanical circulatory support may be beneficial for patients suffering from ARHF. Figure 1 summarizes the management of acute right heart failure. Since most studies have focused on improving left heart function so far, diagnosis and therapy of ARHF has been rarely in the center of research and innovative developments in medical technology. The right ventricle has therefore been named the "forgotten chamber" [3] (Figure 1).

### Acute medical therapy in right heart failure

Most patients suffering from ARHF show an increase in venous filling pressure. However, due to bleeding, sepsis, or other reasons of acute volume loss, infusion of crystalloid solution should be considered to achieve a right arterial filling pressure of at least 10 mmHg. In case of elevated central venous pressure (>15 mmHg), infusion of diuretics in hemodynamically stable patients is recommended [1]. Hemofiltration is indicated in acute renal failure. A combination with mechanical circulatory support should be considered in acute cardiogenic shock.

Secondary causes of ARHF are related to an increase in after load due to obstruction of pulmonary circulation (e.g. pulmonary embolism), chronic pulmonary hypertension, reduction of lung volume due to pleural effusion or pneumothorax, and secondary due to left ventricular dysfunction. Besides causal treatment, i.e. improving left ventricular contractility, thrombolysis, or drainage of the pleural effusion, additional measures for reducing right ventricular after load should be considered in the acute situation. If the patient requires mechanical ventilation, it is recommended to apply low pressure ventilation combined with Nitric Oxide (NO) inhalation for reduction of vascular resistance.

Phosphodiesterase 5 inhibitors increase the endothelial NO production which may contribute to vasodilatation of the pulmonary vasculature. Similar effects can be achieved by direct infusion of NO. However, as NO reduces peripheral vascular resistance, and hence, increases venous pooling, it finally results in a decrease of arterial pressure. Therefore, NO should only be used in hemodynamically stable ARHF patients.

Based on animal studies, dobutamine depicts the substance of choice for improving right ventricular contractility [4]. Dobutamine has beneficial effects restoring right ventricular pulmonary artery coupling and increasing cardiac output compared to nor epinephrine. Phosphodiesterase (PDE) 3 inhibitors should be considered in patients with right heart dysfunction and increased pulmonary artery pressure. PDE 5 inhibitors result in a decrease in pulmonary vascular resistance. They are well established in the treatment of chronic pulmonary hypertension. However, in ARHF their use may be associated with increased hemodynamic instability due to arterial pressure reduction. Despite the improvement of the acute hemodynamic condition, application of PDE inhibitors in ARHF could not show survival benefits as evaluated by randomized clinical studies in high risk cardiac surgery patients [5]. The calcium sensitizer levosimendan improves right ventricular function [6]. It should be considered in secondary right ventricular dysfunction due to left ventricular dysfunction.

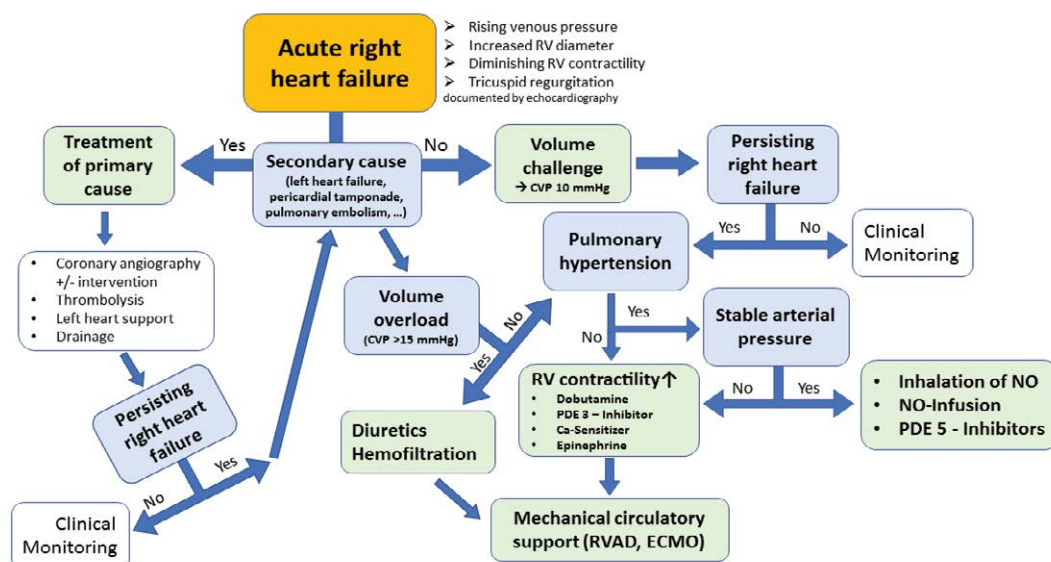
### Mechanical circulatory support in acute right ventricular failure

Extracorporeal Life Support (ECLS) has been increasingly used worldwide, most frequently for left heart failure [7]. It supports patients with cardiopulmonary dysfunction refractory to conventional therapy. Since application of inotropic agent's only results in minor improvements of right heart function in most patients, mechanical circulatory support devices have been developed recently for improving or even replacing the failing right heart. Mechanical assist devices reduce central venous pressure and increase left ventricle filling. The organ perfusion pressure is defined by the difference between mean arterial pressure and central venous pressure. In cardiogenic shock, increasing arterial pressure or decreasing central venous pressure result in an improvement of organ perfusion. Table 1 gives a summary of right ventricular assist devices for minimal invasive implantation in intensive care medicine. Future devices offer higher flow rates at lower vascular access diameters. Animal studies have shown that pulsatile flow maintains hemodynamic stability better than non-pulsatile flow with better preservation of renal function and systemic vascular tone [8]. However, the significance or even necessity of pulsatile support for the failing right ventricle is still unclear (Table 1).

Due to differences in geometry and wall thickness, the process of right ventricular remodeling differs in comparison to the left ventricle. Extracorporeal Membrane Oxygenator (ECMO) systems with centrifugal pumps unload the right ventricle by pumping blood from the vena cava into the aorta [9], hence increasing left ventricular after load [10]. In contrast, Right Ventricular Assist Devices (RVAD) unload the right heart pumping blood from the vena cava into the pulmonary artery increasing right ventricular after load [11]. The reduction in wall tension by ECLS results in a remodeling of the overstretched right

\*Corresponding author: Markus W. Ferrari, Direktor Innere Medizin I, HELIOS Dr. Horst Schmidt Kliniken Wiesbaden, Ludwig-Erhard-Straße 100, 65199 Wiesbaden, Germany. E-mail id: Markus.Ferrari@helios-kliniken.de

Received: November 21, 2017; Accepted: November 27, 2017; Published: December 01, 2017



**Figure 1: Management of acute right heart failure.**

(CVP: Central Venous Pressure; RV: Right Ventricle; PDE: Phosphodiesterase; RVAD: Right Ventricular Assist Device; ECMO: Extracorporeal Membrane Oxygenation with Centrifugal Pump; NO: Nitrite Oxide).

<b>Device:</b>	<b>ECLS - ECMO</b>	<b>Tandem Heart with Avalon Cannula</b>	<b>Impella RP</b>
Cannulation: (Location & Size)	Vena 17 - 23 F Artery 15 – 19 F	Jugular vein 29 F (pre-dilatation)	Femoral vein 23 F (peel-away introducer)
Max. Flow rates:	3 – 6 l/min.	3.7 l/min.	4.4 l/min.
Risk of peripheral ischemia:	+++	++	+
Gas exchange:	Always with MO	Facultative MO	None
Costs:	++	+++	+++

**Table 1:** Mechanical circulatory support for percutaneous implantation in acute right heart failure. (MO: Membrane Oxygenator).

ventricle, thus improving tricuspid valve geometry and reducing valve insufficiency [12]. Hence, ECLS should be considered for recovery in ARHF.

## Future perspectives and challenges

Diagnosis of ARHF is often complex and overlooked in many clinical cases of acute decompensate heart failure. Cardiogenic shock patients with right heart involvement suffer from extremely high mortality rates. Past studies and research mostly focused on improving left ventricular function. Several substances used in intensive care medicine are not validated in ARHF or even contraindicated. Therefore, future developments should focus more on the increasing number of ARHF patients. The proposed algorithm may help improving their clinical outcome.

## References

1. Voelkel NF, Quaife RA, Leinwand LA, Barst RJ, McGoon MD, Meldrum DR, et al. Right ventricular function and failure: report of a National Heart, Lung, and Blood Institute working group on cellular and molecular mechanisms of right heart failure. *Circulation*. 2006; 114: 1883-1891.
2. Alexander JH, Reynolds HR, Stebbins AL, Dzavik V, Harrington RA, Van de Werf F, et al. Effect of tilarginine acetate in patients with acute myocardial infarction and cardiogenic shock: the TRIUMPH randomized controlled trial. *Jama*. 2007; 297: 1657-1666.

3. Rigolin VH, Robilio PA, Wilson JS, Harrison JK, Bashore TM. The forgotten chamber: the importance of the right ventricle. *Cathet Cardiovasc Diagn.* 1995; 35: 18-28.
4. Kerbaul F, Rondelet B, Motte S, Fesler P, Hubloue I, Ewalenko P, et al. Effects of norepinephrine and dobutamine on pressure load-induced right ventricular failure. *Crit Care Med.* 2004; 32: 1035-1040.
5. Denault AY, Bussi eres JS, Arellano R, Finegan B, Gavra P, Haddad F, et al. A multicentre randomized-controlled trial of inhaled milrinone in high-risk cardiac surgical patients. *Can J Anaesth.* 2016; 63: 1140-1153.
6. Parissis JT, Paraskevaidis I, Bistola V, Farmakis D, Panou F, et al. Effects of levosimendan on right ventricular function in patients with advanced heart failure. *Am J Cardiol.* 2006; 98: 1489-1492.
7. Thiagarajan RR, Barbaro RP, Rycus PT, McMullan DM, Conrad SA, Fortenberry JD, et al. Extracorporeal life support organization registry international report 2016. *ASAIO J.* 2017; 63: 60-67.
8. Wang S, Izer JM, Clark JB, Patel S, Pauliks L, Kunselman AR, et al. *In Vivo* hemodynamic performance evaluation of novel electrocardiogram-synchronized pulsatile and nonpulsatile extracorporeal life support systems in an adult swine model. *Artif Organs.* 2015; 39: E90-E101.
9. Rihal CS, Naidu SS, Givertz MM, Szeto WY, Burke JA, Kapur NK,

- et al. 2015 SCAI/ACC/HFSA/STS Clinical expert consensus statement on the use of percutaneous mechanical circulatory support devices in cardiovascular care: endorsed by the american heart association, the cardiological society of india, and sociedad latino americana de cardiologiaintervencion; affirmation of value by the canadian association of interventional cardiology-association canadienne de cardiologie d'intervention. *J Am Coll Cardiol*. 2015. 65: e7-e26.
10. Werdan K, Gielen S, Ebelt H, Hochman JS. Mechanical circulatory support in cardiogenic shock. *Eur Heart J*. 2014; 35: 156-167.
  11. Ferrari M, Kruzliak P, Spiliopoulos K. Spiliopoulos, An insight into short- and long-term mechanical circulatory support systems. *Clin Res Cardiol*. 2015; 104: 95-111.
  12. Spratt JR, Raveendran G, Liao K, John RL. Novel percutaneous mechanical circulatory support devices and their expanding applications. *Expert Rev Cardiovasc Ther*. 2016; 14: 1133-1150.