

## Original Article

# Transthoracic Echocardiography versus Cardiac Magnetic Resonance in Assessment of the Right Ventricle Systolic Function in Patients with Repaired Tetralogy of Fallot. Is there any Correlation Between Tricuspid Annular Plane Systolic Excursion From M-Mode, Tricuspid Annular Systolic Motion From Tissue Doppler Imaging in Transthoracic Echocardiography and the Right Ventricle Ejection Fraction In Cardiac Magnetic Resonance? Results from A UK Centre

Sajnach-Menke M\* and Mauree P

The Newcastle upon Tyne Hospitals NHS Foundation Trust, United Kingdom

## Abstract

**Aims:** The aim of this study was to determine whether tricuspid annular plane systolic excursion from M-mode and tricuspid annular systolic motion from tissue Doppler imaging in transthoracic echocardiogram correlate with the right ventricle ejection fraction in cardiac magnetic resonance and whether they are useful markers in diagnosing the right ventricle dysfunction.

**Methods and results:** 49 patients with repaired tetralogy of Fallot, aged 7 to 53 years, with a mean of 21 years were selected retrospectively. They underwent transthoracic echocardiogram and cardiac magnetic resonance at the Freeman Hospital from January 2008 to June 2016 within 4 months of each other. There were two groups of patients. 24 had normal right ventricle systolic function with ejection fraction  $\geq 45\%$  in cardiac magnetic resonance. 25 had impaired right ventricle systolic function with ejection fraction  $< 45\%$ .

There was a positive relationship between tricuspid annular plane systolic excursion and tricuspid annular systolic motion ( $R=0.65$ ,  $P$ -value=0.05). Median tricuspid annular plane systolic excursion was 1.31 (mean 1.39) in the group of patients with normal right ventricle systolic function and 1.57 (mean 1.57) in the group with impaired right ventricle systolic function in cardiac magnetic resonance. By comparison median tricuspid annular systolic motion was 7.64 (mean 8.24) in the group of patients with normal right ventricle systolic function and 8.84 (mean 9.53) in the group with impaired right ventricle function. The left ventricle ejection fraction was preserved when there was impaired right ventricle ejection fraction in cardiac magnetic resonance ( $P$ -value=0.017).

**Conclusion:** This study demonstrated that tricuspid annular plane systolic excursion and tricuspid annular systolic motion are reproducible measurements of right ventricle systolic function. We did not prove a correlation between tricuspid annular plane systolic excursion, tricuspid annular systolic motion and right ventricle ejection fraction in cardiac magnetic resonance; therefore we concluded that these measurements are not clinically useful markers of right ventricle systolic dysfunction in patients with repaired tetralogy of Fallot. Further studies on larger population involving right ventricle longitudinal strain are necessary to investigate its relationship with right ventricle ejection fraction in cardiac magnetic resonance.

**Units and Abbreviations:** TTE: Transthoracic Echocardiography; CMR: Cardiac Magnetic Resonance; RV: Right Ventricle; TOF: Tetralogy of Fallot; TAPSE: Tricuspid Annular Plane Systolic Excursion; Sa RV: Tricuspid Annular Systolic Motion; TDI: Tissue Doppler Imaging; FAC: Fractional Area of Change; PVR: Pulmonary Valve Replacement

## Introduction

The assessment of the right ventricle is an important part of the follow-up for patients with Fallot tetralogy. Impaired function of the right ventricle is one of the indicators for considering replacement of the pulmonary valve [1].

Echocardiography is used as a preliminary diagnostic imaging method in patients monitored after the correction of tetralogy of Fallot [2]. This is because echocardiography is readily available and widely used

in cardiology. On the other hand, until recently the echocardiography evaluation of the right ventricle was largely qualitative, because the unusual shape of the right ventricle hinders its quantitative assessment. Due to the development of new methods of echocardiography, such as three-dimensional and strain imaging, in the last decade there has been a gradual transition to a more quantitative approach to assess the size and function of the right ventricle.

The quantitative parameters used to assess the right ventricle function are retrospectively divided into geometric and non-geometric parameters. Geometric parameters are based on two-dimensional and three-dimensional measurements of the right ventricular volume. Non-geometric parameters are based on Doppler imaging in the myocardium, tissue Doppler imaging and strain [3,4].

We performed a literature review regarding assessment of the right ventricle with echocardiography. In 2005, the American Society of Echocardiography in conjunction with the European Association of Echocardiography published recommendations about chamber quantification which included norms and abnormal thresholds for tricuspid annular plane systolic excursion and tissue Doppler imaging values. Subsequently, the American Society of Echocardiography

**\*Corresponding Author:** Dr. Sajnach-Menke M, The Newcastle upon Tyne Hospitals NHS Foundation Trust, Newcastle upon Tyne, Freeman Road, NE7 7DN, United Kingdom. E-mail id: magdalena.sajnachmenke@nuth.nhs.uk

**Received:** May 10, 2019; **Accepted:** May 20, 2019; **Published:** May 24, 2018

**Citation:** Sajnach-Menke M, Mauree P. Transthoracic Echocardiography versus Cardiac Magnetic Resonance in Assessment of the Right Ventricle Systolic Function in Patients with Repaired Tetralogy of Fallot. Is there any Correlation Between Tricuspid Annular Plane Systolic Excursion From M-Mode, Tricuspid Annular Systolic Motion From Tissue Doppler Imaging in Transthoracic Echocardiography and the Right Ventricle Ejection Fraction In Cardiac Magnetic Resonance? Results from A UK Centre. *GSL Cardiovasc Dis.* 2019; 1:106.

endorsed by the European Association of Echocardiography proposed a guideline for the echocardiographic assessment of the right heart in adults in 2010. The guideline provides abnormal values for the size and systolic function of the right ventricle and is still widely used in practice.

There are limited studies in which echocardiographic and cardiac magnetic resonance measurement in the assessment of the right ventricle function was compared (Table 1).

Some of them showed that tricuspid annular plane systolic excursion and tissue Doppler imaging are easily measured however, they are angle dependent. There are a few studies which proved that in patients who had tetralogy of Fallot repair, tricuspid annular plane systolic excursion does correlate to the right ventricle ejection fraction measured by cardiac magnetic resonance whilst other studies disproved this earlier theory. It had been shown in these studies that three-dimensional echocardiography systematically underestimated the right ventricle ejection fraction when compared to cardiac magnetic resonance [5,6].

### Imaging values

Tricuspid annular plane systolic excursion represents the distance of systolic excursion of the right ventricle annular plane towards the apex and measures longitudinal right ventricle systolic function (Figure 1). Normal value is above 16mm. Tricuspid annular plane systolic excursion is angle dependent and influenced by the left ventricle function and overall heart motion.

Tricuspid annular systolic motion can be assessed by pulsed tissue Doppler to measure the longitudinal velocity of excursion. This is the measurement of the tricuspid annular velocity at the junction of the right ventricle free wall and the anterior leaflet of the tricuspid valve (Figure 2). Tricuspid annular systolic motion less than 11.5cm/s predicts the right ventricle ejection fraction of less than 45% (Meluzin et al. Martinez-Quintana) [7].

Speckle tracking echocardiography imaging (strain) is angle independent. The distance between natural acoustic markers (speckles) is measured within a predefined myocardial area as a function of time. Strain is a measurement of myocardial deformation. Normal values of longitudinal deformation are between -20 to -25%.

### Purpose

The aim of this study was to determine whether tricuspid annular plane systolic excursion and tricuspid annular systolic motion in transthoracic echocardiography correlate to rejection fraction in cardiac magnetic resonance and hence whether they could be useful markers in diagnosis of the right ventricle systolic dysfunction [8].

### Methods

This is a single centre retrospective study done over period of 09/01/2008 – 06/06/2016 and included patients who had undergone tetralogy of Fallot repair and who had cardiac magnetic resonance and transthoracic echocardiogram within four months of each other. Echocardiography analysis was done from the Freeman Hospital's echocardiography database while the cardiac magnetic resonance reports were obtained from the picture archiving and communications system. A total 110 patients were found to fit the criteria.

### Demographics

61 patients were excluded due to lack of data from echocardiography (no measurements of tricuspid annular plane systolic excursion or tissue Doppler imaging) and therefore the remaining 49 patients who met criteria were included in the study. There were 24 females (49%) and 25 males (51%). 94% of the patients have had transannular patch

repair, 4% had the right ventricle to pulmonary valve conduit insertion and 2% had pulmonary valvotomy as primary tetralogy of Fallot repair. 35% of the patients were post pulmonary valve replacement.

### Results

Descriptive analytical statistics were compiled (Table 2).

There was a positive relationship between tricuspid annular plane systolic excursion and tricuspid annular systolic motion,  $R=0.65$ ,  $P\text{-value}=0.05$ , which is presented in (Table 3).

The patients were split in two groups: 24 patients had normal right ventricle systolic function with ejection fraction  $\geq 45\%$  in cardiac magnetic resonance and the other 25 patients had impaired right ventricle systolic function with ejection fraction  $< 45\%$ . Median tricuspid annular systolic plane excursion was 1.31, mean 1.39 in the group of patients with normal right ventricle systolic function and 1.57, mean 1.57 in the group with impaired right ventricle systolic function, which is visualized in (Table 4).

By comparison median tricuspid annular systolic motion was 7.64, mean 8.24 in the group of patients with normal right ventricle systolic function and 8.84, mean 9.53 in the group with impaired right ventricle systolic function, which is presented in (Table 5).

The left ventricle ejection fraction was preserved when there was impaired right ventricle ejection fraction in cardiac magnetic resonance,  $P\text{-value} 0.017$ , which is presented in (Table 6).

### Discussion

This one of the few studies which compared the assessment of the right ventricle systolic function by echocardiography versus cardiac magnetic resonance in patients with repaired tetralogy of Fallot. It demonstrated that tricuspid annular plane systolic excursion and tricuspid annular systolic motion are reproducible measurements of the right ventricle systolic function [9-11].

We did not prove a relationship between tricuspid annular plane systolic excursion, tricuspid annular systolic motion in echocardiogram and the right ventricle ejection fraction in cardiac magnetic resonance and therefore we concluded that they are not clinically useful markers of the right ventricle systolic function in patients with repaired tetralogy of Fallot.

The right ventricle longitudinal strain is possibly a powerful tool for evaluating the right ventricle function in patients after tetralogy of Fallot repair and there are some prospective studies on small group of patients which show that strain is independently associated with right ventricular ejection fraction derived from cardiac magnetic resonance. It might be useful to plan for prospective studies, ideally including larger multicentre population of patients after tetralogy of Fallot repair to investigate the relationship between strain and the right ventricle systolic function in cardiac magnetic resonance [12].

The fact that there was a preserved right ventricle systolic function despite diminished longitudinal shortening would suggest that the global function of the right ventricle may be more dependent on radial or circumferential contraction. There are some studies which do show that the right ventricle adopts a circumferential contraction pattern, like the left ventricle. Some studies demonstrate a predominance of circumferential strain over longitudinal strain on speckle-tracking echocardiography of the right ventricle.

We demonstrated that in patients with impaired right ventricular ejection fraction left ventricle ejection fraction in cardiac magnetic resonance was still normal. When we consider these results, one question that we should ask ourselves is whether we need to be

**Table 1:**

Article	Type	Findings
Carminati M, Pluchinotta F, Piazza L, Echocardiographic Assessment after Surgical Repair of Tetralogy of Fallot, February 2015, Frontiers in Pediatrics 3:3. [3]	Review article	TAPSE easy to be measured but limitations, not correlating with RV ejection fraction  TDI is angle dependent  Several 2D/3D technologies might enable to investigation of RV function but CMR remains the golden standard  Echocardiography has not decreased the value of cardiac catheters performed but with the added information-has provided more accurate reasoning for invasive investigation
Selly J, Iriart X, Roubertie F, Multivariable assessment of the right ventricle by echocardiography in patients with repaired tetralogy of Fallot undergoing pulmonary valve replacement: a comparative study with magnetic resonance imaging, Arch Cardiovasc.Dis., 2015 Jan;108(1):5-15. doi: 10.1016/j.acvd.2014.07.054. Epub 2014 Nov 12. [6]	Clinical research	TAPSE and RV Sa TDI easily done but insensitive to RV function when compared to CMR  Echocardiography underestimates consistently RV ejection fraction compared to CMR and correlation between two modes of investigations worse dilated RV  FAC correlates greatly with CMR but feasibility remains limited
Senthilnathan S, Dragulescu A, Mertens L, Pulmonary Regurgitation after Tetralogy of Fallot Repair: A Diagnostic and Therapeutic Challenge, J. Cardiovasc.Echogr.2013 Jan-Mar;23(1):1-9. doi: 10.4103/2211-4122.117975. [8]	Review article	RV z-scores and RV end diastolic area can be used to identify patients with significant RV dilatation  2D-based 3D reconstruction currently is the most reliable accurate echocardiographic method for quantifying RV volumes, and is emerging as a potential alternative to CMR  FAC can be used for assessment of RV function. TDI and TAPSE correlate only weakly with RV ejection fraction as they only assess RV inlet
Koestenberger M, Friedberg M, Ravekes W, Non-Invasive Imaging for Congenital Heart Disease: Recent Innovations in Transthoracic Echocardiography, January 2012, Journal of Clinical and Experimental Cardiology Suppl 8(Suppl 8):2. [10]	Review article	Recent publications suggest importance of TAPSE in RV function investigation, TAPSE correlated to RV ejection fraction in adults  After a mean of 6.1 year after TOF repair, TAPSE values become abnormal and decrease showing RV dysfunction likely secondary to volume overload secondary to PR  In TOF patients measured by MRI, and inverse and significant correlation was found between TAPSE and RVEF  Limitation of TAPSE – good overall RV function indicator but does not consider segmental function differences

concerned with right ventricular systolic function at all since the left ventricular function is preserved.

The prevalence of speckle-tracking echocardiography, especially when minimizing the subjective judgment of the performer, creates new possibilities to assess the right ventricle systolic function [13-15].

Indeed, there will need to be more studies to answer the crucial question of whether strain could be used as a tool for the assessment of the right ventricle systolic function.

### Limitations

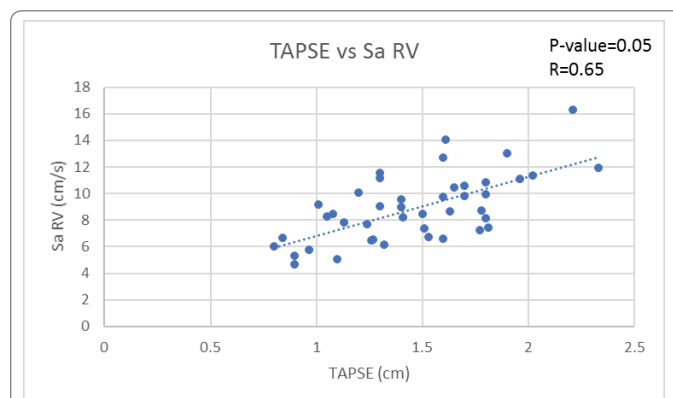
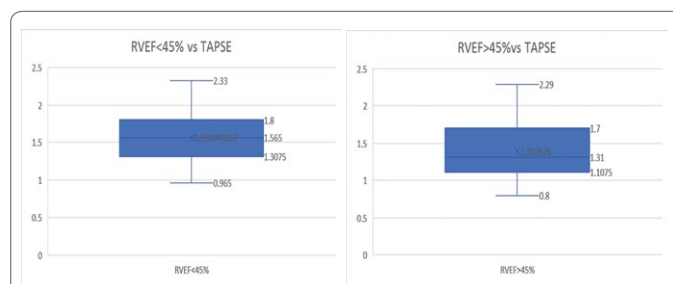
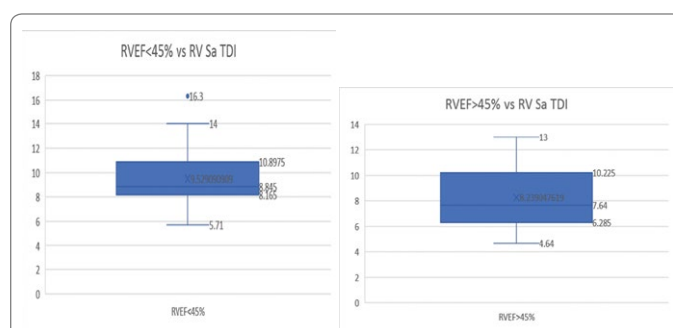
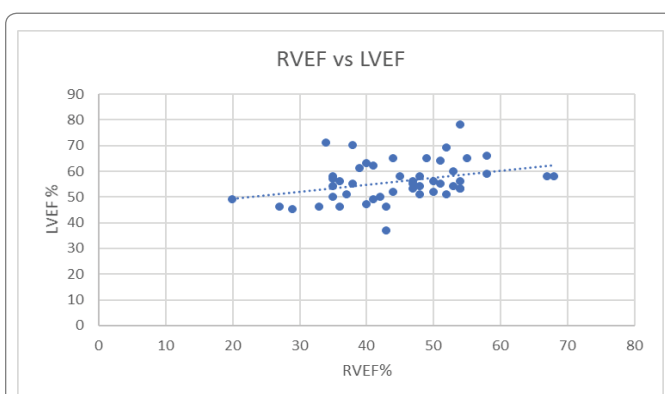
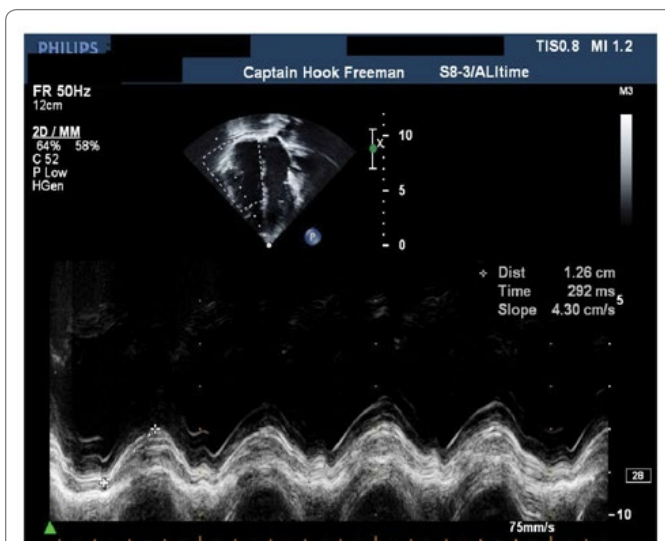
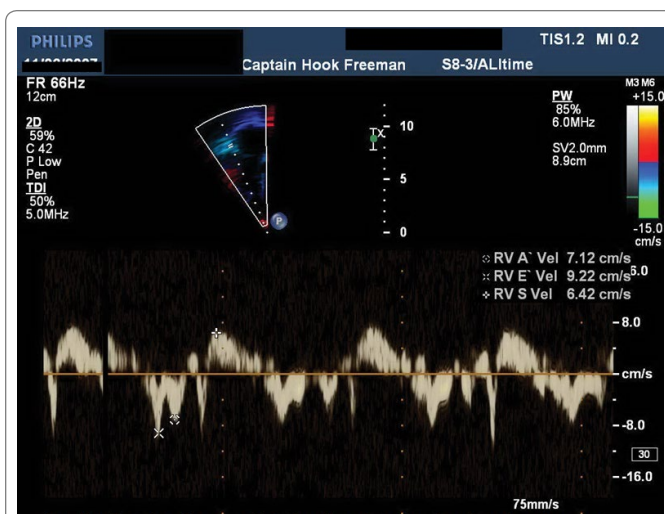
This study was retrospective. The small sample size and angle dependent measurements of tricuspid annular plane systolic excursion and tricuspid annular systolic motion were the main limitations of our study.

### Conclusion

This study demonstrated that tricuspid annular plane systolic excursion and tricuspid annular systolic motion are reproducible measurements of the right ventricle systolic function. We did not prove a correlation between tricuspid annular plane systolic excursion, tricuspid annular systolic motion and the right ventricle ejection fraction in cardiac magnetic resonance, therefore we concluded that these measurements are not clinically useful markers of the right ventricle systolic dysfunction in patients with repaired tetralogy of Fallot. Further studies on larger population involving the right ventricle longitudinal strain are necessary to investigate its relationship with the right ventricle ejection fraction in cardiac magnetic resonance.

**Table 2:** Clinical characteristics.

Characteristics	Results
Mean TAPSE (cm) in TTE	1.5±0.4
RV Sa (cm/s) in TTE	8.95±2.5
Normalised RVEDV (ml/m <sup>2</sup> ) at CMR	130±39
RVEF (%) in CMR	44.9±9.7
LVEF (%) in CMR	56±7.8

**Table 3:** Relationship between TAPSE and Sa RV.**Table 4:** TAPSE in TTE in patient with impaired versus normal right ventricle systolic function in CMR.**Table 5:** Sa RV in TTE in patient with impaired versus normal right ventricle systolic function in CMR.**Table 6:** Left ventricle systolic function versus right ventricle systolic function in CMR.**Figure 1:** Normal value of tricuspid annular plain systolic excursion (TAPSE).**Figure 2:** Normal value of tricuspid annular systolic motion (RV Sa).

## Acknowledgment

The authors thank Alison Heads-Baister - Head of Echocardiogram Department and all the echocardiogram technicians at the Freeman Hospital.

## References

1. Nishimura R, Otto C, Bonow R, et al. (2014) AHA/ACC Guideline for the Management of Patients with Valvular Heart Disease. A Report of the American College of Cardiology/American Heart Association Task Force on Practice Guidelines. *J Am Coll Cardiol*. 63: 57-185.
2. Carminati M, Pluchinotta F, Piazza L, et al. (2015) Echocardiographic Assessment after Surgical Repair of Tetralogy of Fallot. *Front Pediatr*. 3: 3.
3. Lang R, Bierig M, Devereux R, et al. (2005) Recommendations for Chamber Quantification: A Report from the American Society of Echocardiography's Guidelines and Standards Committee and the Chamber Quantification Writing Group, Developed in Conjunction with the European Association of Echocardiography, a Branch of the European Society of Cardiology. *J Am Soc Echocardiogr*. 18:1440-1463.
4. Salehian O, Burwash IG, Chan KL, et al. (2008) Tricuspid annular systolic velocity predicts maximal oxygen consumption during exercise in adult patients with repaired tetralogy of Fallot. *J Am Echocardiogr*. 21: 342- 346.
5. Hashimoto I, Watanabe K, Ichida F. (2015) Right to left ventricular diameter ratio  $\geq 0.42$  is the warning flag for suspecting atrial septal defect in preschool children: age- and body surface area-related reference values determined by M-mode echocardiography. *Pediatric Cardiol*. 37: 704-713.
6. Selly J, Iriart X, Roubertie F, et al. (2015) Multivariable assessment of the right ventricle by echocardiography in patients with repaired tetralogy of Fallot undergoing pulmonary valve replacement: a comparative study with magnetic resonance imaging. *Arch Cardiovasc Dis*. 108: 5-15.
7. Martinez-Quintana E, Rodriguez-Gonzales F, Marin J, et al. (2012) Assessment of right ventricular function in significant pulmonary regurgitation after surgical correction of tetralogy of Fallot and pulmonary stenosis. *J Clin Exp Cardiol*. 3: 194.
8. Senthilnathan S, Dragulescu A, Mertens L. (2013) Pulmonary Regurgitation after Tetralogy of Fallot Repair: A Diagnostic and Therapeutic Challenge. *J Cardiovasc Echogr*. 23: 1-9.
9. Bleeker G, Steendijk P, Holman E, et al. (2006) Assessing right ventricular function: the role of echocardiography and complementary technologies. *Heart*. 2006; 92: 19-26.
10. Koestenberger M, Friedberg M, Ravekes W, et al. (2012) Non-Invasive imaging for congenital heart disease: recent innovations in transthoracic Echocardiography. *J Clin Exp Cardiol*. 8: 2.
11. Pavlicek M, Wahl A, Rutz T, et al. (2011) Right ventricular systolic function assessment: rank of echocardiographic methods vs. cardiac magnetic resonance imaging. *Eur J Echocardiogr*. 12: 871-880.
12. Almeida-Morais L, Pereira-da-Silva T, Branco L, et al. (2016) The value of right ventricular longitudinal strain in the evaluation of adult patients with repaired tetralogy of Fallot: a new tool for a contemporary challenge. *Cardiology in the Young*. 1: 1-9.
13. Hayabuchi Y, Sakata M, Kagami S. (2015) Right ventricular myocardial deformation patterns in children with congenital heart disease associated with right ventricular pressure overload. *Eur Heart J Cardiovasc Imaging*. 16: 890-899.
14. Rudski L, Wyman W, Afilalo J, et al. (2010) Guidelines for the echocardiographic assessment of the right heart in adults; A report from the american society of echocardiography endorsed by the european association of echocardiography, registered branch of the European Society of Cardiology, and the Canadian Society of Echocardiography. *J Am Soc Echocardiogr*. 23: 685-713
15. Moen C, Salminen P, Dahle G, et al. (2013) Is strain by Speckle Tracking Echocardiography dependent on user controlled spatial and temporal smoothing? An experimental porcine study, cardiovascular Ultrasound. 11: 32.